Dr Louise O'Toole
Consultant Ophthalmologist
Mater Private Hospital
Dublin

NON RETINAL OCULAR COMPLICATONS OF DIABETES

Cranial Nerve Palsies

- Oculomotor
- Abducens
- Trochlear

Cranial Nerve Palsies

- Oculomotor
  Pupil Sparing

Cranial Nerve Palsies

- Abducens

Cranial Nerve Palsies

- Trochlear

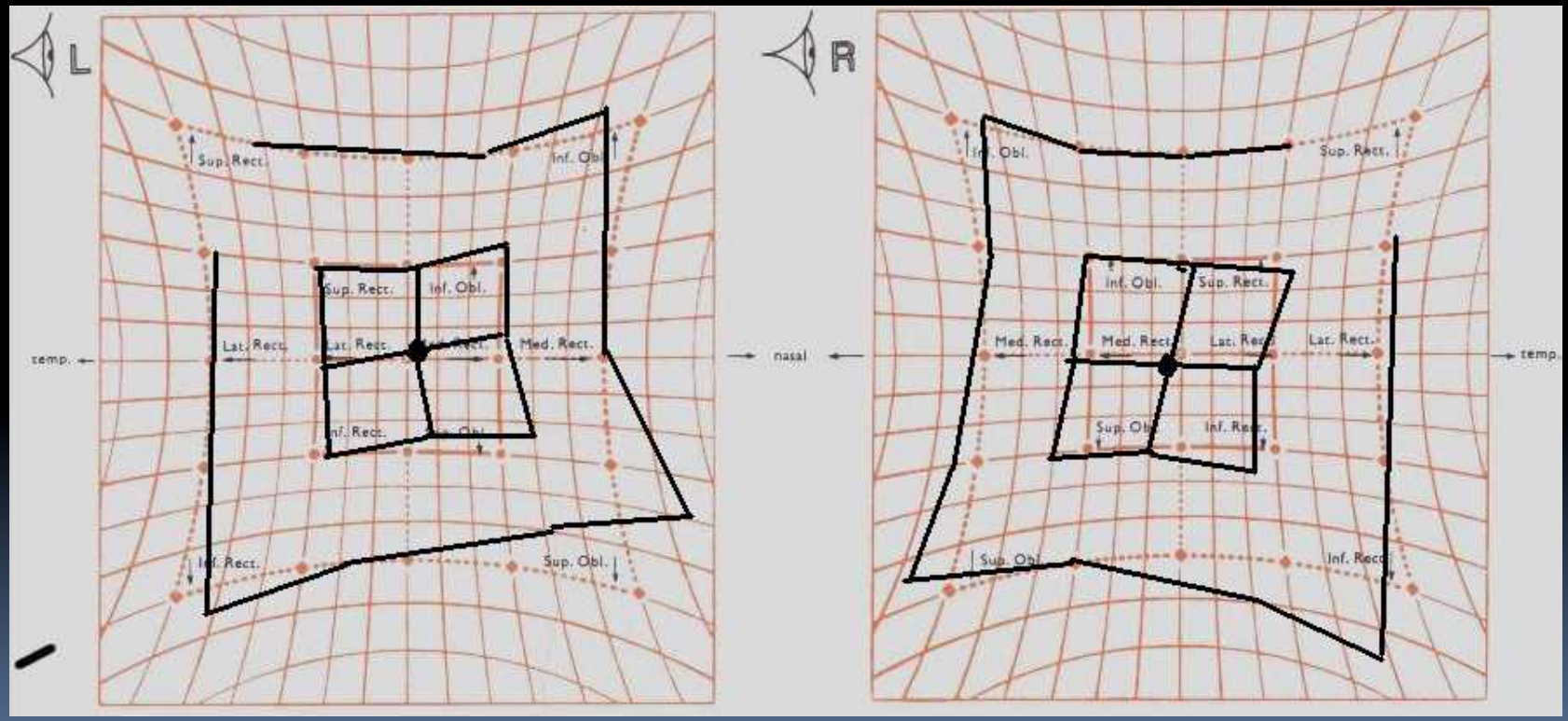

Chalazia

Corneal Ulceration

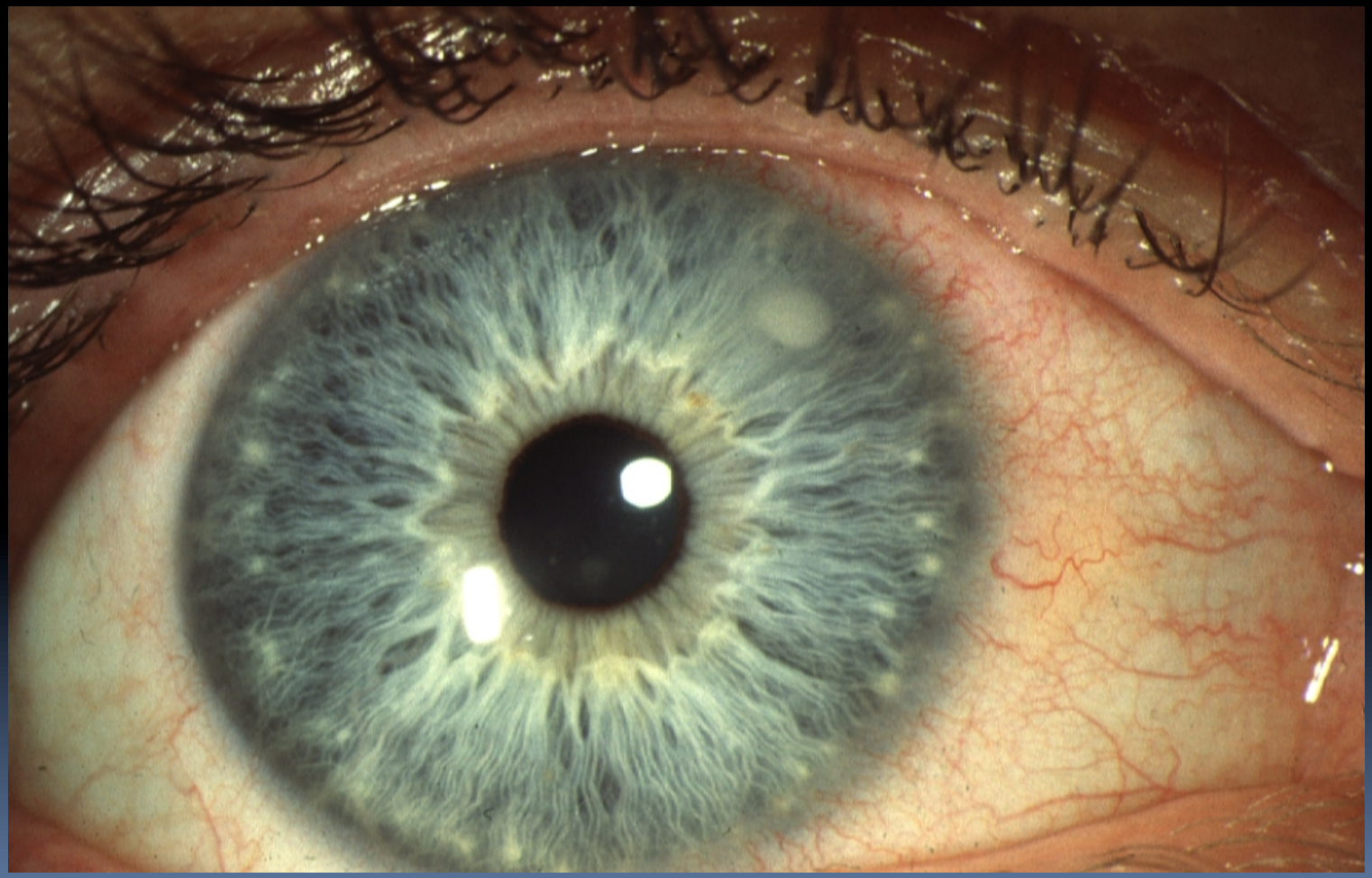

Glaucoma

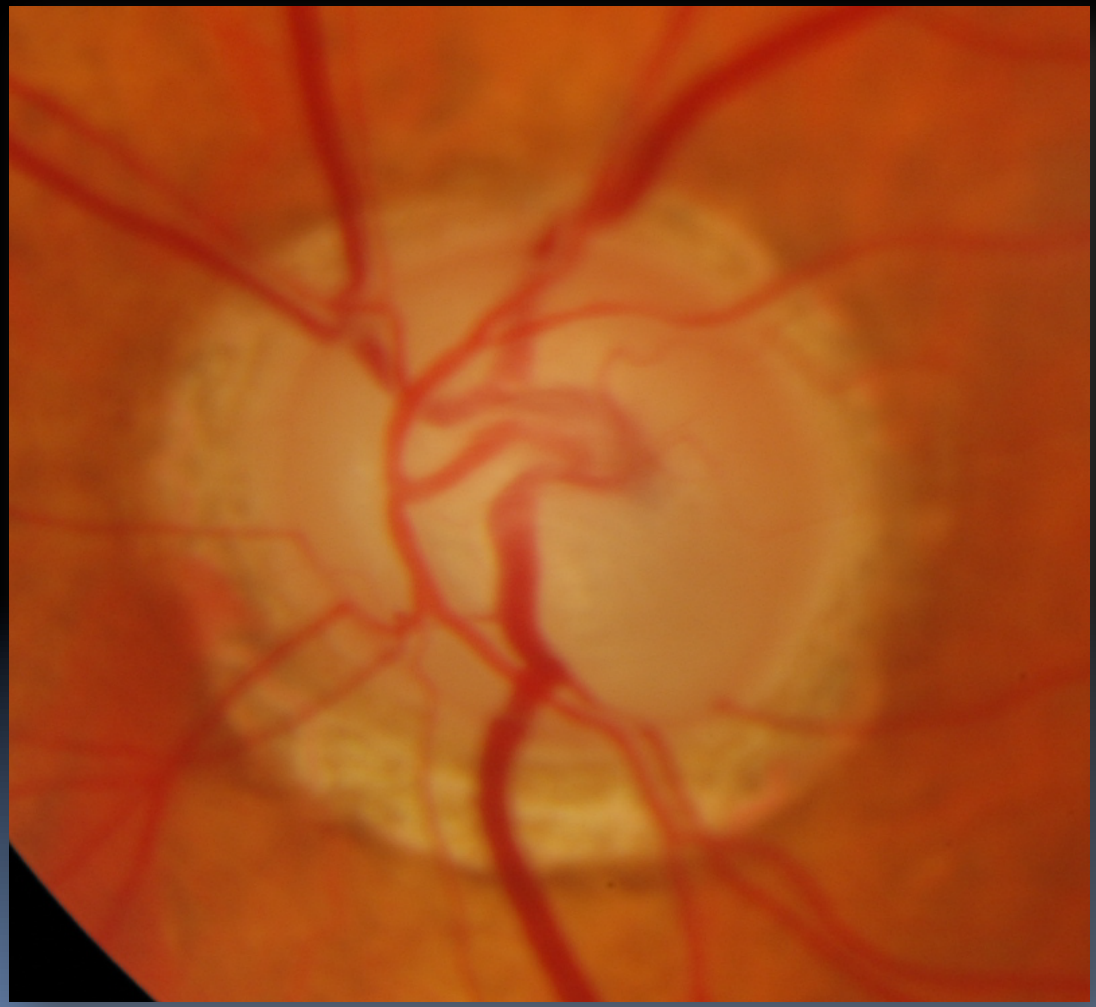

Glaucoma

Cataracts

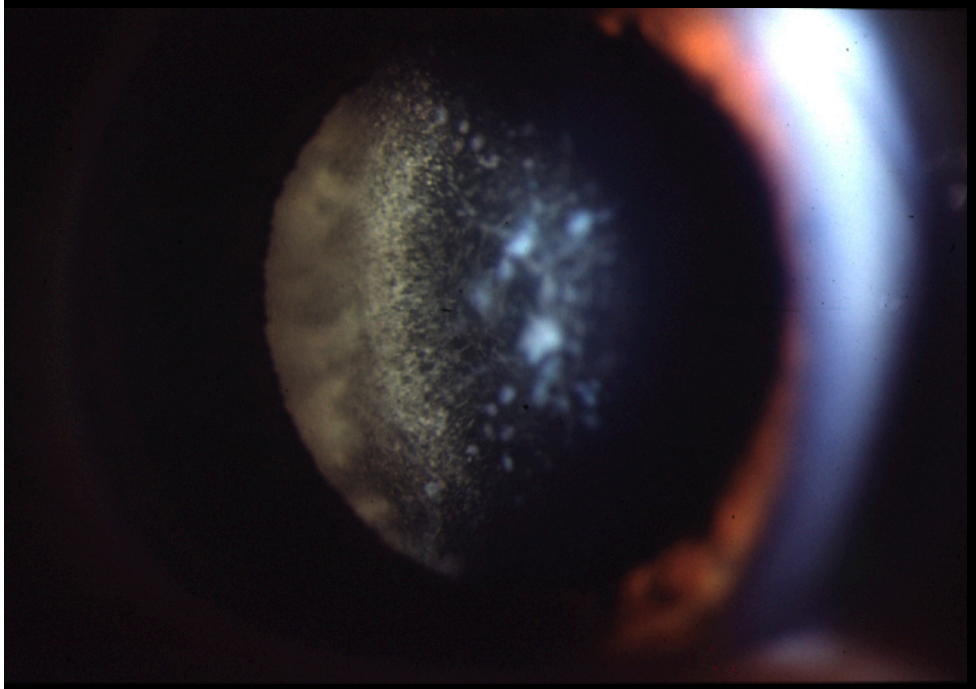

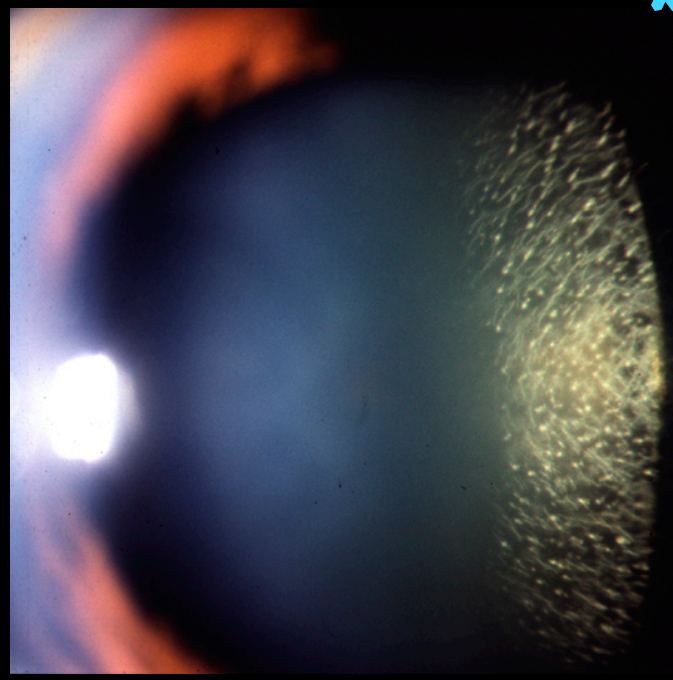

Cataracts

Refractive Fluctations

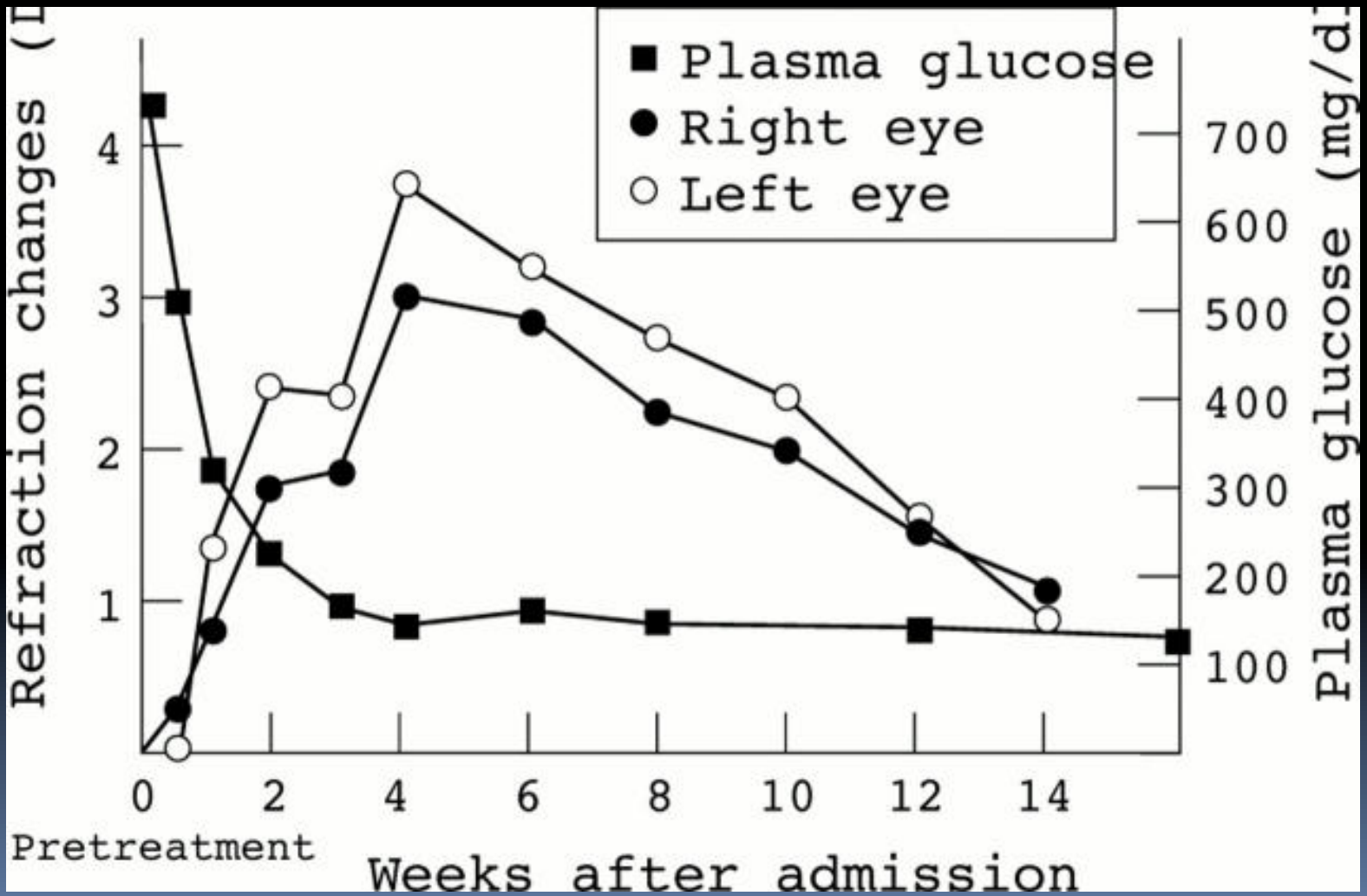

Iris

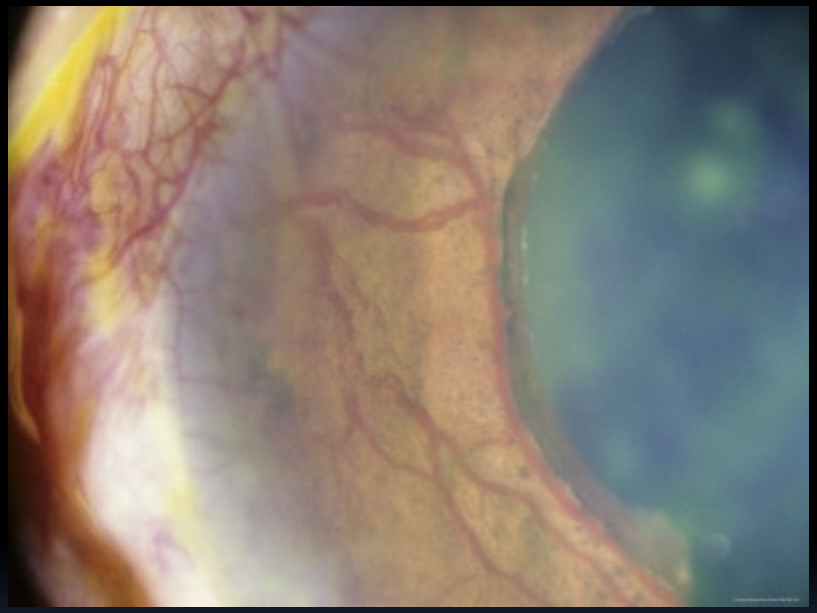

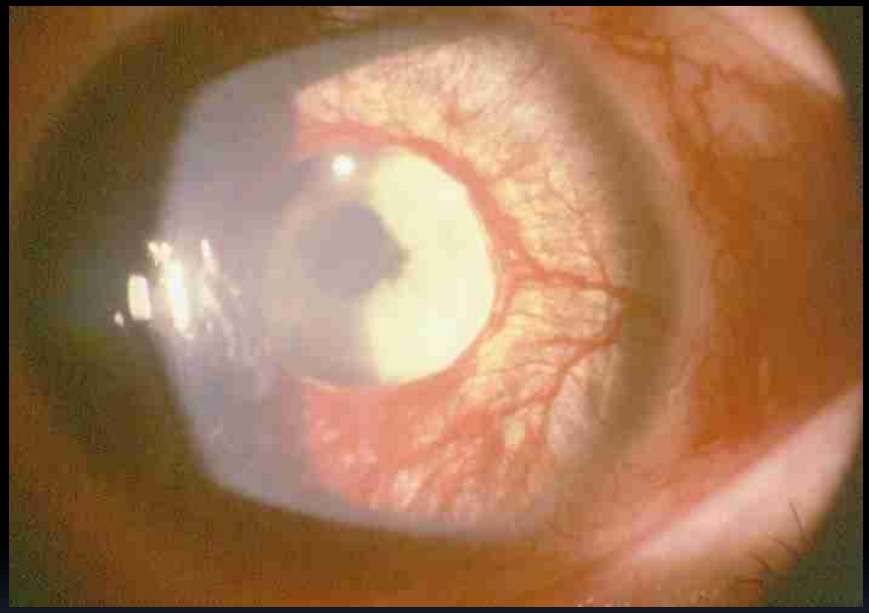

Vein Occlusions

BRVO

CRVO

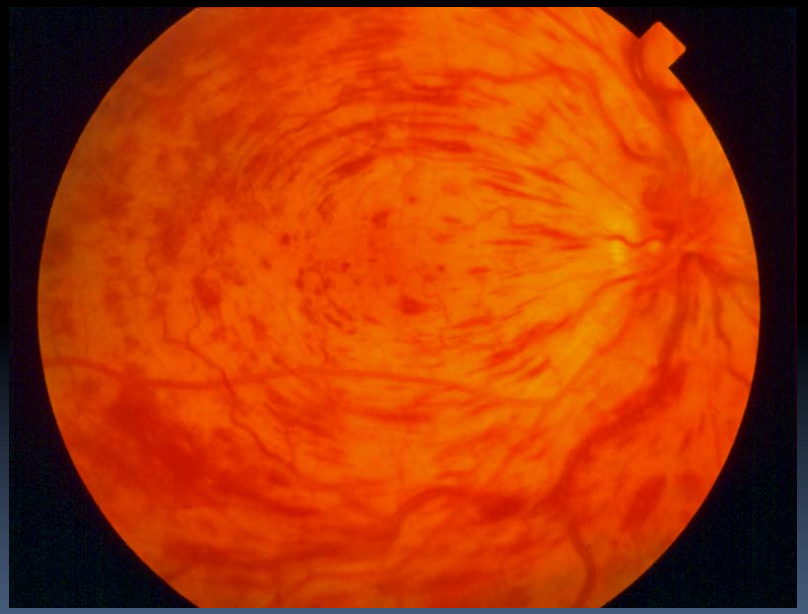

Non Arteritic Ischaemic Optic Neuropathy NAION

Infarction of the short ciliary arteries

Sudden, painless loss of vision, usually noticed in the morning

Can progressively worsen

Patients usually > 45yrs Arteriopaths

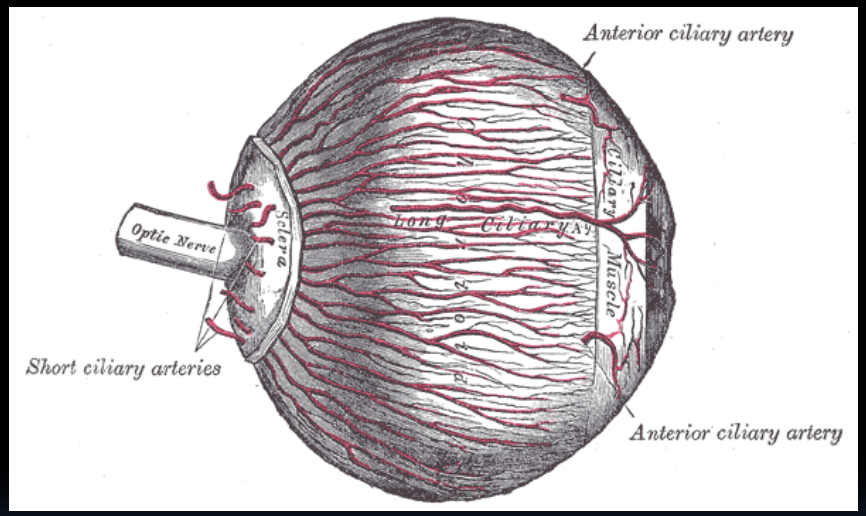

Non Arteritic Ischaemic Optic Neuropathy NAION

Altitudinal field defect

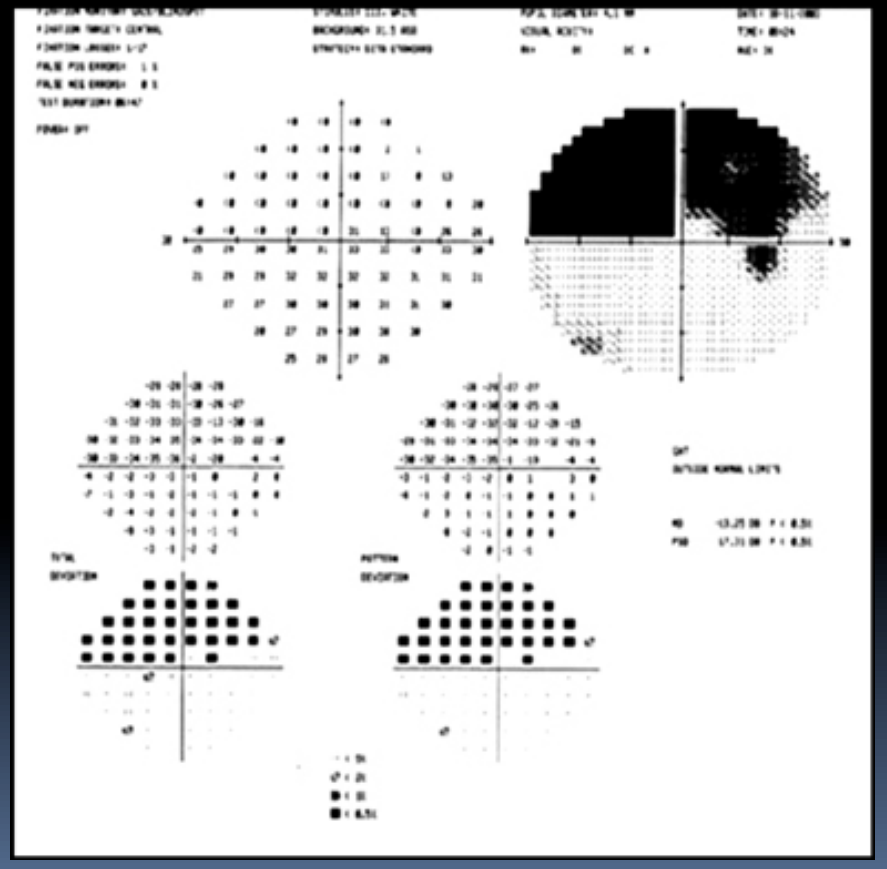

Non Arteritic Ischaemic Optic Neuropathy NAION

- Diffuse or segmental disc swelling
- Hemorrhages & CWS
- Small discs or discs with drusen have an increased risk of NAION
- Fellow eye will be affected within 5 years in up to 20%.

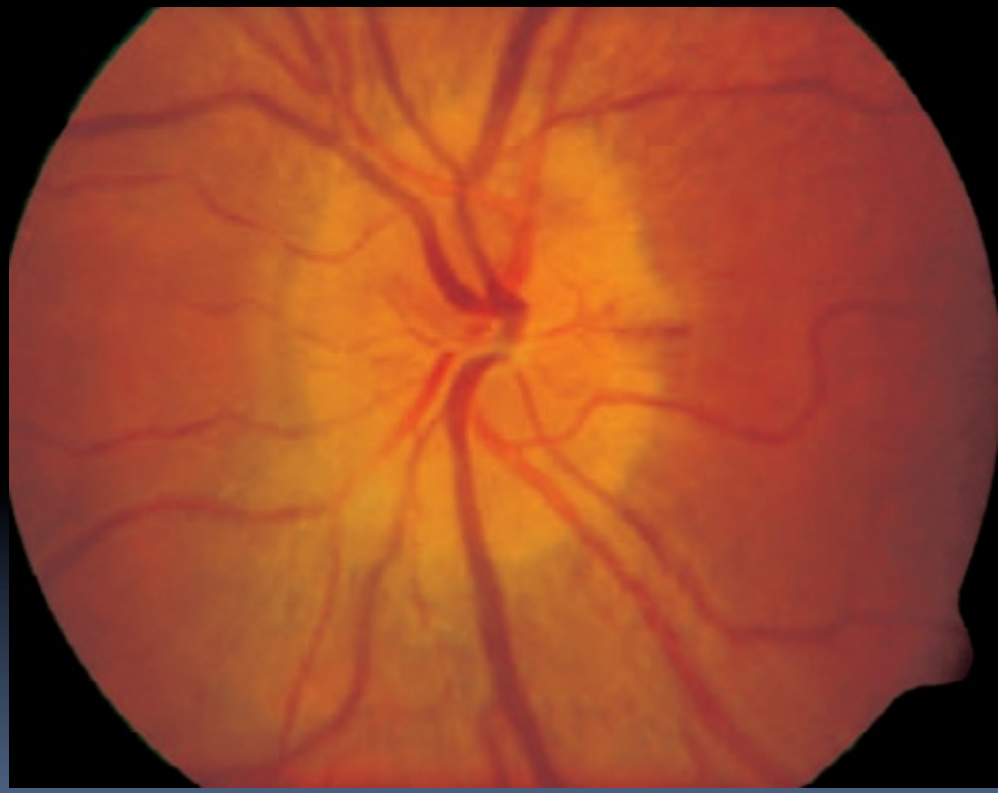

Non Arteritic Ischaemic Optic Neuropathy NAION

- Within 6 to 12 weeks segmental disc pallor
- Antiplatelet drugs are given prophylactically

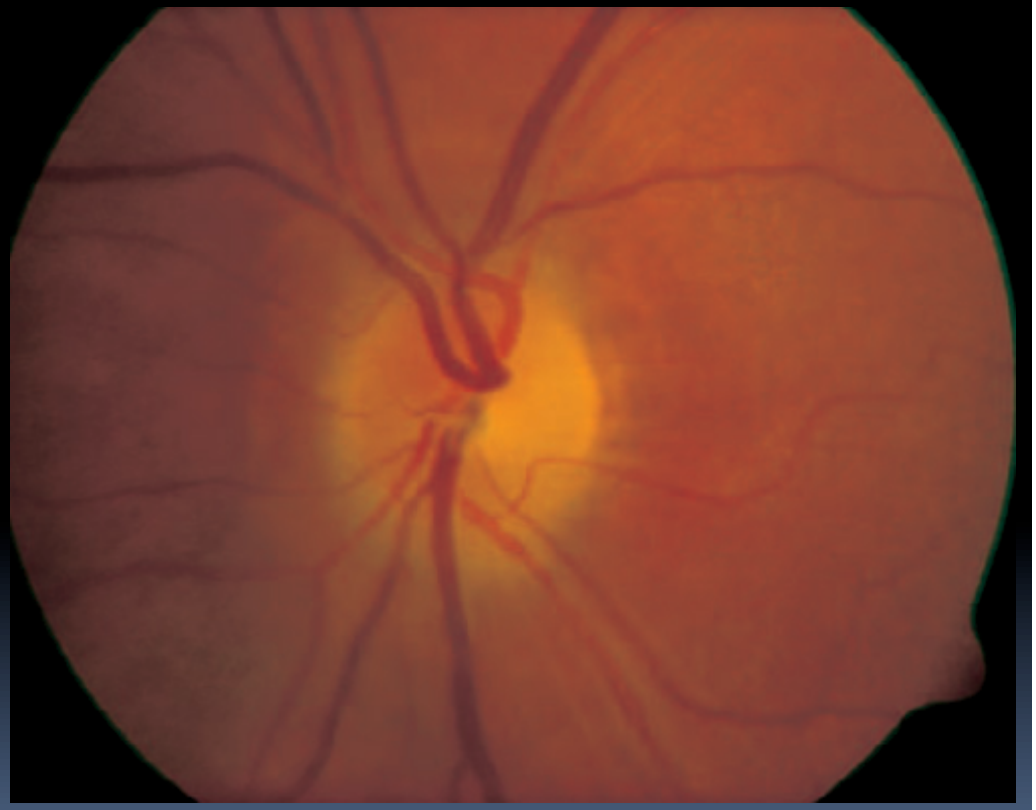

Comorbid Conditions

Diabetes.
Now's the
time to
fight back.
Together we can beat
the silent assassin.

Start doing this
Keep doing this
Stop doing this